

# Implant Supported Overdenture for the Atrophic Mandible

*Lakshman Dene, D.D.S., B.D.S., M.Med.Sc., Ph.D.*

## **Abstract**

A long-term denture wearer exhibited advanced alveolar bone loss, resulting in an atrophic mandible. Symphyseal bone height was 10 mm. The inferior alveolar nerve and mental foramen were close to the crest of the mandible. The symphyseal region was available for endosteal implant placement. Patient was an 83-year-old white male who was medically compromised. Anticoagulant therapy was stopped and INR evaluated prior to implant surgery. With the help of computerized tomography, four Nobel Biocare Tapered TiUnite narrow platform implants were placed anteriorly between the mental foramina. An implant-supported mandibular overdenture was fabricated. Locator attachments provided retention and stability for the prosthesis. This helped improve the patient's quality of life.

IT IS ESTIMATED that 8% of the U.S. population is edentulous in one or both dental arches. The age group 65 and older is projected to increase from 12% to 20% in the next 25 years. The rate of edentulism increases with age, resulting in people 75 years and older being 44% edentulous.<sup>1</sup> The maxilla is more frequently edentulous than the mandible. It is, however, in the mandible that dentures cause problems and much unhappiness, resulting in a decreased quality of life.<sup>2,3</sup> Therefore, restoration of the edentulous mandible, especially the atrophic one, is a challenge.

Tooth extraction is followed by a loss of bone width by 25% and a loss in bone height of 4 mm during the first year.<sup>4</sup> The loss of bone width occurs on the labial aspect of the alveolar ridge, resulting in the residual ridge being shifted to the lingual. With removable denture wearers, bone loss continues over the years. If, however, endosteal implants are placed and the bone is stimulated by forces transmitted to the bone from implants, the bone loss is minimal. In long-term denture wearers, the bone loss may be extensive. After many years, the alveolar ridge is completely resorbed, leaving only the basal bone. The absence of the alveolar ridge compromises the retention and stability of the dentures.

With advanced bone loss, the mandibular dentures become non functional.<sup>3</sup>

Atrophic edentulous ridges in the mandible have many problems. There is a loss of width and height of alveolar bone. The symphyseal height of bone may be about 10 mm to 11 mm. The loss of alveolar bone would result in prominent internal oblique ridges and the genial tubercles; therefore, increased sore spots and exaggerated movements in the mandibular dentures would be observed. The atrophic mandible would also result in muscle attachments, such as the buccinator and mylohyoid being close to the crest of the ridge, thereby elevating the prostheses during function. Paresthesia may occur due to dehiscence of the neurovascular bundle. There is loss of facial height, resulting in poor esthetics. There is also a risk of mandibular fracture.

The ability to restore the atrophic mandible with endosteal implants has revolutionized dentistry.<sup>5</sup> This could be accomplished by fabricating an implant-supported, fixed prosthesis, bar-retained FP 4 prosthesis or a FP 5 tissue-supported implant overdenture.<sup>1</sup> For a fixed prosthesis, bone volume must be increased with autogenous block grafts from the Illiac crest.<sup>6</sup> This method of bone grafting is least

desirable as there is an additional surgical site, increased morbidity and cost.

Transosteal implants using an extraoral approach is another form of fixed prosthesis with similar disadvantages.<sup>6</sup> A minimally invasive and less-expensive method is to place endosteal implants in the anterior mandible between the mental foramina. An overdenture is fabricated, which is either bar retained or tissue supported. This case was designed to place endosteal implants in the interforaminal area.<sup>6</sup> The prosthesis was fabricated with locator attachments and was tissue borne.

### Clinical Case

The patient was an 83-year-old white male. His chief complaint was that he was unable to eat and enjoy his food. He said his lower denture was very loose, and he requested that we make it stable. He had been a full denture wearer for 40 years. The alveolar bone was completely resorbed, resulting in an atrophic mandible in which some basal bone had been resorbed as well. The symphyseal height of the anterior mandible was 10 mm (Figure 1).

The patient's medical history was significant, with predominantly cardiovascular problems. These included congestive heart failure, cardiomyopathy and atrial fibrillations. He was on multiple medications, including digoxin, flomax, lanoxin, lisinopril, furosimide and warfarin. He had no known drug allergies.

Based on his medical history, consultation with his cardiologist was done prior to surgical treatment. Since he was on warfarin (coumadin) anticoagulant therapy, medical management of this patient was very important.

### Management of Anticoagulant Therapy Prior to Surgery


Anticoagulant therapy is used to prevent blood clot formation. The level of anticoagulation is determined by the prothrombin (PT) time. This measures the extrinsic pathway of coagulation. The normal PT is 12 to 15 seconds. Because tissue factors used in determining PT times were from different batches and manufacturers, the International Normalized Ratio (INR)

was introduced to standardize results. Each manufacturer gives an International Sensitivity Index (ISI) for the tissue factor it makes. The ISI indicates how the particular batch of tissue factor compares to an internationally standardized sample. The ISI is usually between 1.0 and 1.4.<sup>7</sup>

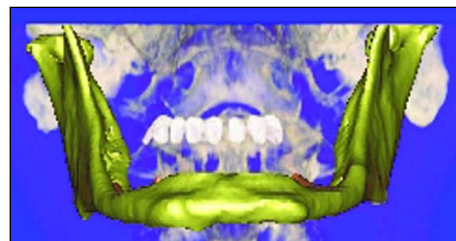
The INR is a ratio of the PT time for the test sample divided by the PT time for the normal control sample as a function of ISI. In a healthy patient, the INR value is 0.8 – 1.2. When managing patients with cardiovascular events, such as this patient, the target INR range is 2.0 – 3.0. For patients with prosthetic heart valves, it is 2.5 – 3.5. Surgery performed on patients with these INR values could result in considerable hemorrhage. Coumadin was stopped for five days. The INR was dropped to 1.2 prior to surgery.

### Computerized Tomography

Location of the inferior alveolar nerve during its passage in the mandible is an important landmark that needs to be evaluated



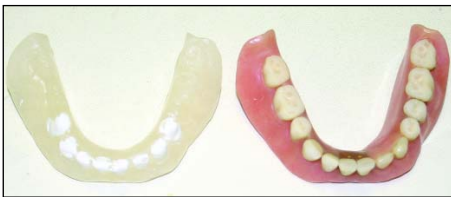
**Figure 1.** Computerized tomogram showing symphyseal bone height and superior location of inferior alveolar nerve and mental foramen in atrophic mandible.



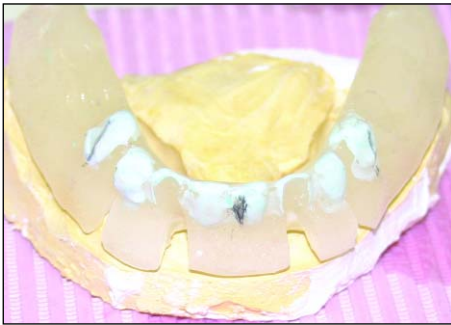**Figure 2.** Three-dimensional view of atrophic mandible with superior location of mental foramen and its relation to mandibular denture.

prior to implant placement. Its location vertically in relation to the alveolar ridge and inferior border of the mandible and its position bucco-lingually is important. The exact location of the mental foramen and the presence or absence of an anterior loop need to be determined. The identification

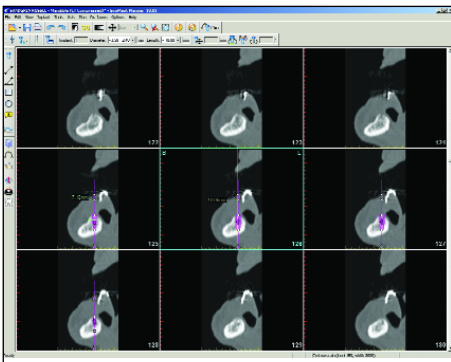




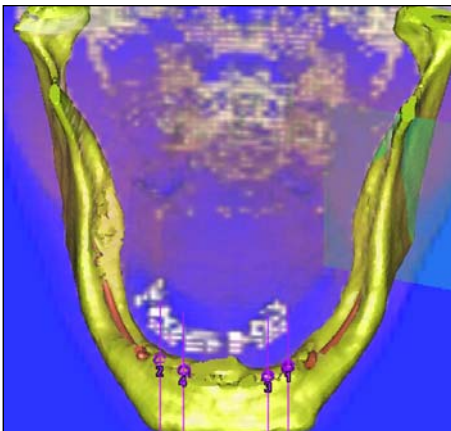
**Figure 3.** Radiographic template (duplicate denture with barium sulphate painted on teeth).



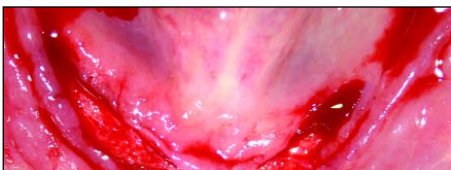
**Figure 4.** Surgical template (converted diagnostic template).



**Figure 5.** Height and width of anterior mandible. CT scan—cross sections.



**Figure 6.** CT scan showing 3D image of implant positions anterior to mental foramen.



**Figure 7.** Surgical site: Supra-crestal incision anterior to mental foramina.

of these anatomical landmarks is of greater importance in the atrophic mandible.

The position of the inferior alveolar nerve and mental foramen could be determined with periapical or panoramic X-rays. However, the distortion observed in periapical X-rays is 14%, and 23% with panoramic X-rays, which is significant.<sup>8</sup> Also, the bucco-lingual position of these structures cannot be visualized by these two-dimensional radiographic techniques.

Computerized tomography allows visualization in three dimensions: the x-axis (mesiodistally); the y-axis (vertically); and the z-axis (bucco-lingually). The distortion level is only 1.8% and will allow determining the position of these anatomical structures with accuracy. The exact position of the inferior alveolar nerve can be traced in the mandible with the use of Simplant (Materialise, Glen Burnie, MD).

In this patient, the inferior alveolar nerve was close to the crest of basal bone because of the advanced resorption following the wearing of dentures for 40 years. The position of the mental foramen was at the crest (Figures 1,2). The radiographic template is also seen in this picture.

### Fabrication of Radiographic Diagnostic Template

To visualize the position of teeth in relation to the mandibular ridge in CT scans, it is necessary to fabricate a diagnostic (radiographic) template that the patient wears during the CT scan procedure. This was accomplished by duplicating the patient's existing mandibular denture. A denture-duplicating flask, ortho-jet, fast-curing orthodontic resin and an aquapress were used (Lang, Dental Manufacturing Co., Inc., Wheeling, IL). The teeth were painted with barium sulphate. This makes them radioopaque in the CT scan and allows identification of tooth positions suitable for implant placement (Figures 2,3).

### Surgical Implant Placement

The diagnostic template was transformed into a surgical template for implant surgery (Figure 4). The surgical template helped to identify the tooth positions and their location on the mandible. The symphyseal

height in this mandible was 10 mm. The bucco-lingual width was 7 mm. This restricted the choice of implants to a narrow platform 8 mm in length. Also, the bone had a density of 500 to 600 Hounsfield units (D3) (Figures 5,6).

CT scan revealed that the inferior alveolar nerve was positioned close to the crest of the ridge, and the mental foramina were at the crest; therefore, implant locations were restricted to the mandibular symphyseal area. The patient was premedicated with antibiotics. Surgery was performed under local anesthesia. Supracrestal incisions were made 5 mm anterior to the positions of the mental foramina. Buccal and lingual full thickness mucoperiosteal flaps were raised. Using the surgical guide, Nobel Biocare Tapered Tiunite implants 3.5 mm by 8 mm were placed at teeth #22, #23, #26 and #27 locations. Surgical cover screws were placed, and the flaps were approximated with primary closure (Figures 7,8,9).

The patient was told not to wear the lower denture for two weeks following surgery. The sutures were removed in two weeks and the denture was soft relined (Lynal). This allowed the patient to wear the removable prosthesis during the period of osseointegration without transmitting excessive forces to the surgical sites.

### Second Stage/Uncovery Surgery

The coumadin was stopped for five days to allow the INR to go down to 1.0 – 1.5. At this stage, the implants were exposed, the surgical cover screws were removed and the sites were irrigated with sterile normal saline. Healing collars were placed, and the gingival tissues were allowed to mature for one month.

### Selection of Locators and Fabrication of Mandibular Dentures

The depth of each crevice was measured with a periodontal probe following the removal of each healing collar. Locators (Zest Anchors, Inc., Escondido, CA) corresponding to the crevice depth were placed and torqued to 30 N cm with the locator tool and torque wrench. Locator transfer posts

were placed and a polyvinyl siloxane impression was taken in a closed tray. Locator analogs were placed on the transfer posts before seating into the impression. The corresponding males were sent to the lab, together with the impression to be incorporated into the denture for retention and stability (Figures 10,11,12).

## Discussion

The ability to restore an edentulous arch with endosteal implants revolutionized dentistry. This resulted in a paradigm shift and opened up numerous approaches to restore edentulous arches.<sup>5</sup> This patient was a long-term denture wearer. At the time he started wearing a mandibular prosthesis, implants were not a treatment option. The 40 years of wearing dentures resulted in extensive bone resorption. The resorption was such that the inferior alveolar nerve was close to the alveolar crest. The mental foramina exited at the mandibular crest. The extensive bone resorption resulted in prominent anatomic structures being close to the crest of the ridge. This caused exaggerated movements of the denture and frequent sore spots. The result was a decreased quality of life.

Medical management of the older patient presents additional challenges. This was true in this patient, as he had cardiovascular complications. In addition, he was on anticoagulants, which made it necessary to bring down his INR to 1.0 – 1.5 prior to surgery. The patient tolerated the surgery very well. Postoperative complications were minimal. Healing was uneventful.

A CT scan is mandatory for these patients. The exact position of the inferior alveolar nerve and the location of the mental foramina are very important. Once identified, the implants were placed 5 mm anterior to the mental foramen to account for the anterior loop that might exist.

The radiographic diagnostic template was converted to a surgical stent for implant surgery. This is a valuable tool. It provides information about the position of the teeth on the ridge. It would also enable locating the position of the mental foramen in relation to the position of teeth on the ridge. This is significant, because damage

to the mental nerve could be avoided preventing paresthesia or dysesthesia.

Successful restoration of the atrophic mandible with endosteal implants without bone augmentation had been reported.<sup>9,10,11</sup> This case supports those observations. In this case, the mandible was restored with four narrow platform implants. Using locator attachments, a mandibular overdenture was fabricated with good retention and stability. This improved the patient's quality of life.

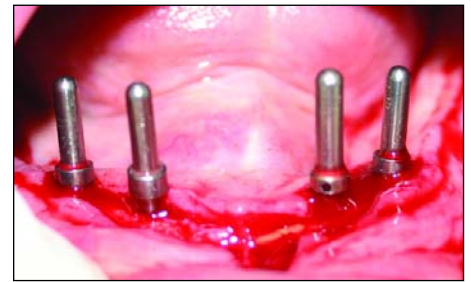
## Conclusion

For patients with advanced bone loss in the mandible, there is hope for a better quality of life. This report demonstrates the successful use of endosteal implants together with locators in the mandibular symphyseal area. This improves retention and stability of the lower denture. ■

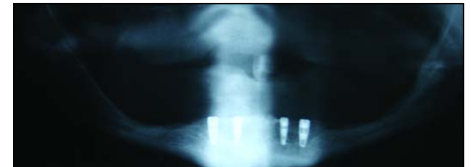*Queries about this article can be sent to Dr. Dene at lakshdene@hotmail.com.*

## REFERENCES

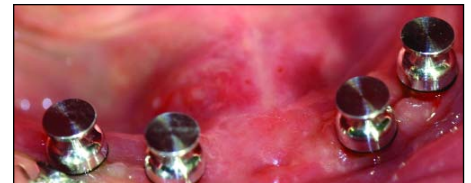1. Misch CE. Contemporary Implant Dentistry: Third Edition. St. Louis, MO: Mosby Elsevier. 2008.
2. Van Wass MA. The influence of clinical variables on patient satisfaction with complete dentures. *J Prosthet Dent* 1990;63:307-310.
3. Meijer HJ, Raghoobar GM, van't Hof MA, Greetman, ME, van Oort RP. Implant retained mandibular overdentures compared with complete dentures: 5 years' follow up study of clinical aspects and patient satisfaction. *Clin Oral Implants Res* 1999;10: 238-244.
4. Carlsson G, Persson G: Morphologic changes of the mandible after extraction and wearing of dentures: a longitudinal clinical and X-ray cephalometric study covering 5 years. *Odontol Revy* 1967;18:27-54.
5. Branemark Per-Ingvar, Zarb GA, Albrektsson T. Tissue integrated prosthesis. In: Osseointegration in Clinical Dentistry. Quintessence Publishing Co., Inc. 1985.
6. Stellingsma K, Raghoobar GM, Meijer Henny JA, Stegenga B. The extremely resorbed mandible. A comparative prospective study of 2 year results with 3 treatment strategies. *J Oral & Maxillofac Implants* 2004;19(4):563-577.
7. Goodman LS, Brunton LL, Gilman A, et al. Goodman and Gilman's The Pharmacological Basis of Therapeutics. Chapter 54: Blood Coagulation and Anticoagulant, Thrombolytic and Antiplatelet Drugs. McGraw Hill. 2005.
8. Sonick M, Abrahams J, Faiella R. A comparison of the accuracy of periapical, panoramic and computerized tomographic radiographs in locating the mandibular canal. *J Oral & Maxillofac Implants* 1994;9(4):455-460.
9. Stellingsma C, Meijer HJ, Raghoobar BM. Use of short endosseous implants and overdentures in the extremely resorbed mandible. A five-year retrospective study. *J Oral & Maxillofac Surg* 2000;58:382-387.
10. Pavlatos J. The root supported overdentures using locator overdenture attachment. *Gen Dent* 2002:
11. Schneider A. Placement of an implant stabilized complete denture. A case report. *Prac Proc & Aesthetic Dent* 2004;16(8):3-6.



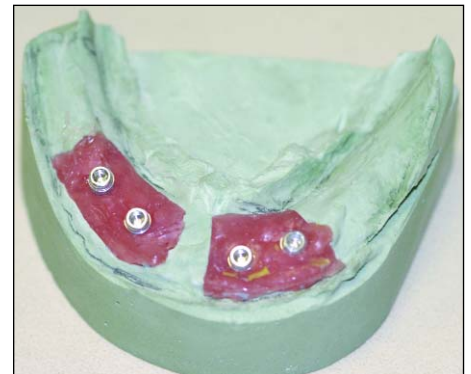
**Figure 8.** Implant osteotomies and parallelism.



**Figure 9.** Postoperative panoramic radiograph showing implant positions.



**Figure 10.** Locators with transfer posts ready for impression.



**Figure 11.** Laboratory master cast with locator analogs in place.



**Figure 12.** Final prosthesis.



*Lakshman Dene, D.D.S., B.D.S., M.Med.Sc., Ph.D., is clinical assistant professor in the Surgical & Prosthetic Implant Program at New York University College of Dentistry, New York, NY. He maintains a cosmetic, restorative and implant practice in Patchogue, Long Island, NY.*

Dr. Dene